

## 4 Cords: A case report of spontaneous quadruplet pregnancy

### 4 Cordões: Relato de um caso de gravidez espontânea de quadrigêmeos

Carolina Mendonça<sup>1</sup>, Inês Jorge<sup>1</sup>, Diana Martins<sup>1</sup>  
Hospital Beatriz Ângelo

#### Abstract

We present a case of a 32-year-old woman with a spontaneous quadruplet pregnancy, managed with careful prenatal care. Despite the inherent risks of multiple gestations, including gestational diabetes and preterm labor, the patient declined multifetal pregnancy reduction. Comprehensive monitoring, including biweekly ultrasounds, early intervention for cervical shortening, and the administration of betamethasone, contributed to a successful outcome. At 30 weeks, a cesarean section was performed, resulting in four healthy neonates. This case highlights the importance of individualized management in high-order pregnancies and the successful delivery of healthy infants despite significant challenges.

**Keywords:** Multiple pregnancy; Quadruplets; Spontaneous pregnancy; Prenatal care; Preterm birth.

#### Resumo

Relata-se o caso de uma gravidez espontânea de quadrigêmeos, que culminou numa cesariana pré-termo às 30 semanas de gestação, da qual resultaram quatro recém-nascidos vivos. Apesar da recusa materna em realizar redução multifetal perante um risco obstétrico significativamente aumentado – nomeadamente diabetes gestacional e parto pré-termo – a implementação de uma vigilância pré-natal intensiva permitiu alcançar um desfecho favorável. O plano de seguimento incluiu ecografias quinzenais, monitorização seriada do comprimento cervical e administração precoce de corticosteroides (betametasona) após diagnóstico de encurtamento cervical. Este caso reforça a importância de uma abordagem multidisciplinar e individualizada na gestão de gravidezes múltiplas de elevada ordem, demonstrando a possibilidade de desfechos perinatais positivos mesmo em contextos clínicos de risco elevado.

**Palavras-chave:** Gravidez de alto risco; Quadrigêmeos; Vigilância pré-natal; Redução multifetal; Prematuridade.

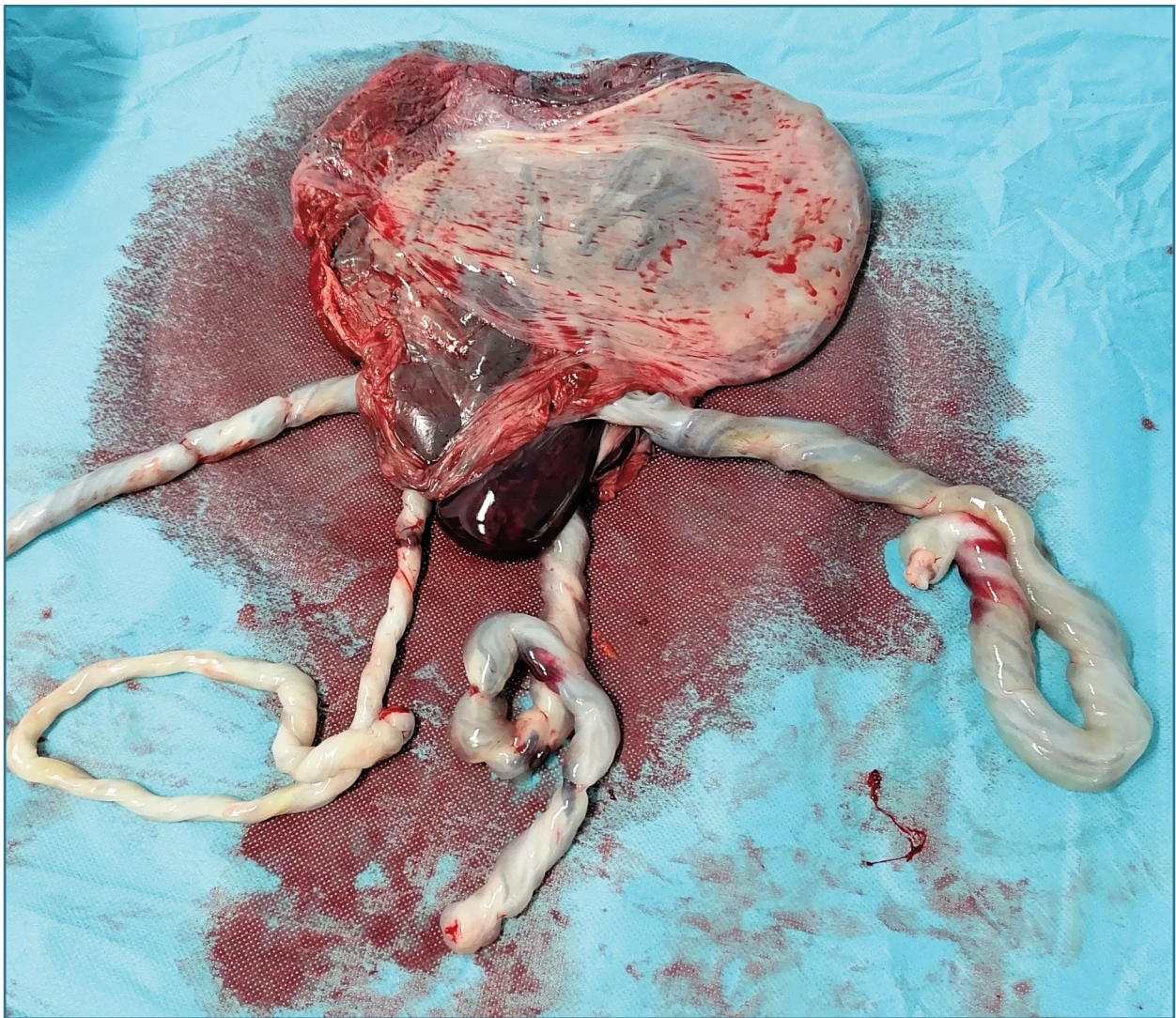
#### INTRODUCTION

Higher-order pregnancies (>2 fetuses), which predominantly arise from ovarian stimulation and assisted reproductive technology (ART)<sup>1</sup>, can also occur spontaneously, particularly in women of advanced ma-

ternal age<sup>2</sup>. In 2021, the triplet and higher-order multiple birth rate in United States was 80.0 per 100,000 births, with quadruplet births accounting for just 0,000036% of the total<sup>3</sup>.

Multiple gestations carry a significantly increased risk of maternal, fetal, and neonatal complications, such as: early or late fetal loss, preterm labour and delivery, low birth weight, and increased perinatal mortality<sup>1,2,4</sup>. Such pregnancies often result in a higher proportion of

1. Hospital Beatriz Ângelo.



**FIGURE 1.** 3 placentas and 4 umbilical cords.

infants with very low birth weight or prematurity-related complications.

While preventing multiple gestations through better management of ART is ideal, in cases where preventive interventions fail or when spontaneous conception occurs, procedures for multifetal pregnancy reduction have been developed to improve outcomes by reducing the number of fetuses<sup>4,5</sup>. Nonetheless, patient autonomy remains paramount, and some women opt not to undergo reduction despite the risks.

The outcomes of these pregnancies depend on the number of fetuses, the quality of obstetric and neonatal

care, and the individual management strategy employed. Given the rarity of quadruplet pregnancies, comprehensive guidelines for their management are lacking.

Here, we present a successful case of a spontaneous quadruplet pregnancy, emphasizing the role of tailored prenatal care and close monitoring.

## CASE REPORT

A 32-year-old woman, G3P2, with a history of depres-

sion, asthma, and gestational diabetes was referred to Hospital Beatriz Ângelo for first-trimester screening after a spontaneous conception. Initial ultrasound revealed a trichorionic quadrigeminal pregnancy, with two monochorionic/biamniotic fetuses. Multifetal pregnancy reduction was offered to mitigate the risks associated with higher-order pregnancies, but the patient declined. During the second trimester, the patient was diagnosed with gestational diabetes, which was managed effectively with metformin, maintaining reasonable glycemic control. Biweekly ultrasounds showed normal fetal growth, no signs of twin-to-twin transfusion syndrome; and only a mild pyelectasis detected in fetus 1.

At 28 weeks, a cervical shortening of 14 mm was detected. She was admitted and treated with vaginal progesterone and administered betamethasone to promote fetal lung maturity in anticipation of preterm labor. At 30 weeks, she underwent a cesarean section following the spontaneous onset of labor. Four healthy newborns were delivered: a male weighing 1024 g, a female weighing 1056 g, another female weighing 1076 g, and a second male weighing 1201 g, all with good Apgar scores. Placental examination revealed fused discs and no pathological abnormalities.

The mother had an uneventful postoperative recovery, and the newborns were discharged after 42 to 47 days, following stabilization from complications such as retinopathy, hyaline membrane disease, jaundice, and gastroesophageal reflux.

## CONCLUSION

This case highlights the importance of tailored prenatal care in managing spontaneous higher-order pregnancies. Despite the risks, the patient's decision to decline multifetal reduction led to the successful delivery of four healthy infants. Vigilant monitoring, early com-

plication detection, and timely interventions were key to the outcome. Sharing cases like this may guide clinical decisions, support the development of structured follow-up protocols, and improve care strategies for higher-order multiple pregnancies.

## REFERENCES

1. Abu-Heija AT. Maternal and neonatal outcome of high order gestation. *Arch Gynecol Obstet.* 2003;268(1):15-8.
2. Wen SW, Demissie K, Yang Q, Walker MC. Maternal morbidity and obstetric complications in triplet pregnancies and quadruplet and higher-order multiple pregnancies. *Am J Obstet Gynecol.* 2004;191(1):254-8.
3. Osterman MJK, Hamilton BE, Martin JA, Driscoll AK, Valenzuela CP. National Vital Statistics Reports Volume 72, Number 1 January 31, 2023. 2021;72(1):15-44.
4. Committee P, Society A. Multiple gestation associated with infertility therapy: An American Society for Reproductive Medicine Practice Committee opinion. *Fertil Steril.* 2012;97(4):825-34.
5. Too G, Berkowitz RL. Multifetal pregnancy reduction. *Obstetric Imaging: Fetal Diagnosis and Care*, 2nd Edition. 2017;58(3):495-498.e1.

## AUTHOR'S CONTRIBUTION

Carolina Mendonça performed the literature search, collected the data, wrote the article and is the guarantor and corresponding author. Inês Jorge assisted with the literature search. Diana Martins was involved in providing critical revisions for important intellectual content and assisted with the editing and proofreading of the manuscript.

## CONFLICTS OF INTEREST

There are no conflicts of interest, and informed consent was obtained.

## CORRESPONDENCE TO

Carolina Mendonça

E-mail: carolinamrodrigues94@gmail.com

<https://orcid.org/0000-0002-4515-0921>

**RECEIVED:** 13/01/2025

**ACCEPTED:** 07/04/2025