

# Uterine smooth muscle tumour of uncertain malignant potential (STUMP): an unexpected diagnosis in an unusual location

## Tumor muscular liso de comportamento maligno incerto (STUMP): um inesperado diagnóstico numa incomum localização

Lisandra Melo Mendonça<sup>1</sup>, Sónia Gonçalves<sup>1</sup>, António Santos Paulo<sup>1</sup>, Nuno Dias<sup>1</sup>, Rita Mesquita Pinto<sup>1</sup>  
Unidade Local de Saúde Viseu Dão-Lafões

### Abstract

STUMP is considered a rare subtype of smooth muscle tumor whose incidence is unknown, but whose location is predominantly uterine. According to the WHO classification, it presents intermediate criteria between benign and malignant, and its histopathological classification is not consensual. This case describes a clinical and surgical approach of a 44-year-old woman who was referred to a gynecology consultation due to the insidious appearance of a vaginal mass with apparently benign characteristics, whose histological study after excision revealed the presence of a mesenchymal tumor with STUMP characteristics.

**Keywords:** STUMP; Smooth muscle tumor; Leiomyoma; Leiomyosarcoma; Vagina.

### Resumo

O STUMP é considerado um subtipo raro de tumor do músculo liso cuja incidência é desconhecida, mas cuja sua localização é predominantemente uterina. Segundo a classificação da OMS, apresenta critérios intermédios entre benignidade e malignidade, sendo a sua classificação histopatológica não consensual. Este caso descreve a abordagem clínica e cirúrgica de uma mulher de 44 anos que foi referenciada à consulta de ginecologia por aparecimento insidioso de uma formação vaginal com características aparentemente benignas cujo estudo histológico após a excisão revelou a presença de um tumor mesenquimatoso com características de STUMP.

**Palavras-chave:** STUMP; Tumor do músculo liso; Leiomioma; Leiomiossarcoma; Vagina.

### INTRODUCTION

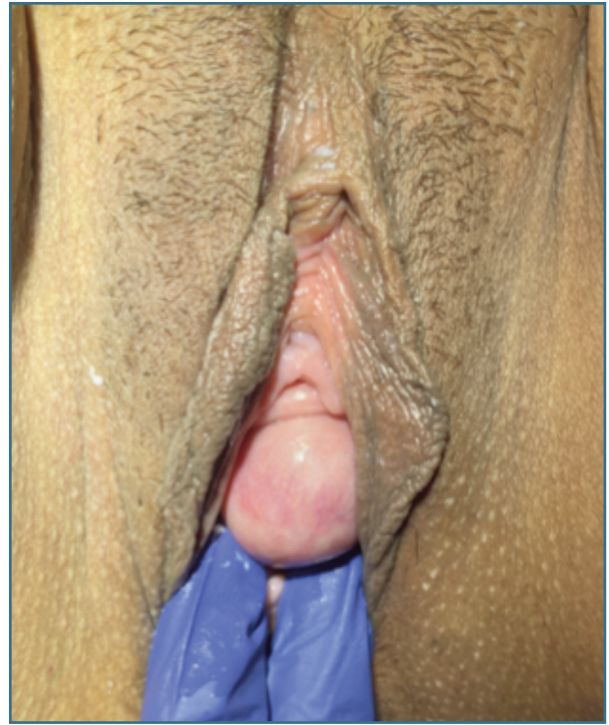
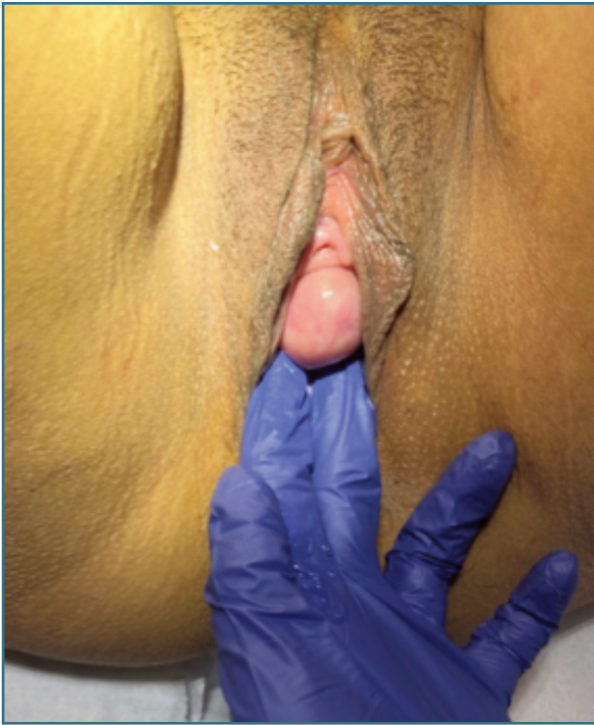According to the 2014 World Health Organization (WHO) classification, the uterine smooth muscle tumours of uncertain malignant potential (STUMP) are rare tumours with pathological characteristics analogous to leiomyosarcoma, but that do not satisfy histological criteria for leiomyoma<sup>1</sup>. Thereby, the pathological diag-

nosis of STUMP is founded on the presence of coagulative necrosis, the finding of 24 mitoses per field and moderate focal atypia and diffuse moderate atypia<sup>2-4</sup>.

The average age of onset for this pathology is 45 years old, and it mostly appears during the premenopausal stage of reproductive life, comparable to that of fibroids and sarcomas<sup>4-5</sup>.

There are no clinical guidelines on the management of STUMP, so the clinical approach to the diagnosis, treatment and control of its recurrence is established

1. ULS Viseu Dão-Lafões.



**FIGURE 1 & 2.** Vaginal nodular formation in gynaecological exam.

on observational studies<sup>6-7</sup>. Currently, data have shown that uterine diagnostic criteria are universal for smooth muscle tumors originating in the ovary, vulva, vagina, broad ligament, and other supportive connective tissue. As in the uterus, vulvovaginal STUMPs are an even rarer heterogeneous group of smooth muscle tumours (SMT) with potential for recurrence. The most recent WHO Classification of Tumours of Female Reproductive Organs cites a recurrence rate up to 26.7% for uterine STUMPs depending on their morphologic findings<sup>8</sup> but other studies revealed rates between 8,7%-11% and this discordance can be due to underdiagnosis<sup>9</sup>.

The clinical presentation of vaginal STUMPs resembles that of uterine leiomyomas and includes rapidly growing pelvic mass, pressure symptoms and pelvic pain<sup>10</sup>. The risk factors and biological events that lead to STUMP aren't widely understood and thus clinical behaviour is unpredictable<sup>11</sup>.

Moreover, it has been suggested in various data, that a strict follow-up after surgery should involve a clinical evaluation performed every 6 months in the first 5 years combined with a yearly total-body computed tomography scan (CT), followed by annual surveillance

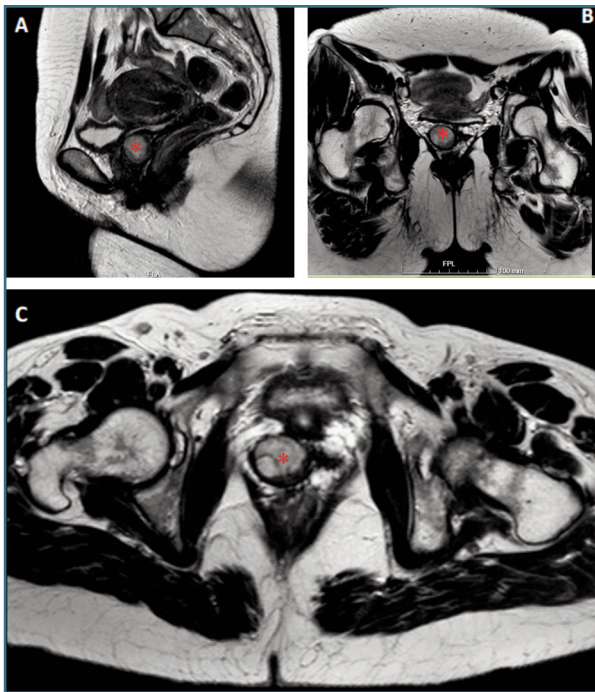for the next 5 years<sup>12</sup>. Nevertheless, patients should always be counselled regarding the potential risk of recurrence as leiomyosarcoma and a multidisciplinary management should be carried out by a team including oncological gynaecologist, specialized pathologist and oncologist for early detection of recurrence and decide treatment options.

The main purpose of this article is to describe the clinical and surgical approach of a woman with a histological diagnosis of a vaginal STUMP.

## CASE REPORT

A 44-year-old woman was referred to a gynaecological appointment due to an insidious growing of a vaginal mass. She was a healthy woman with no relevant personal or family history nor regular use of medication. At the time, the only complaint she presented was mild discomfort during sexual intercourse.

On physical exam, the patient showed a spherical formation in the lower third of the anterior vaginal wall, with about 4 cm (Figures 1 and 2). The mass was



**FIGURE 3.** Vaginal nodular formation (\*) in MRI in the sagittal (A) and axial plane (B and C).

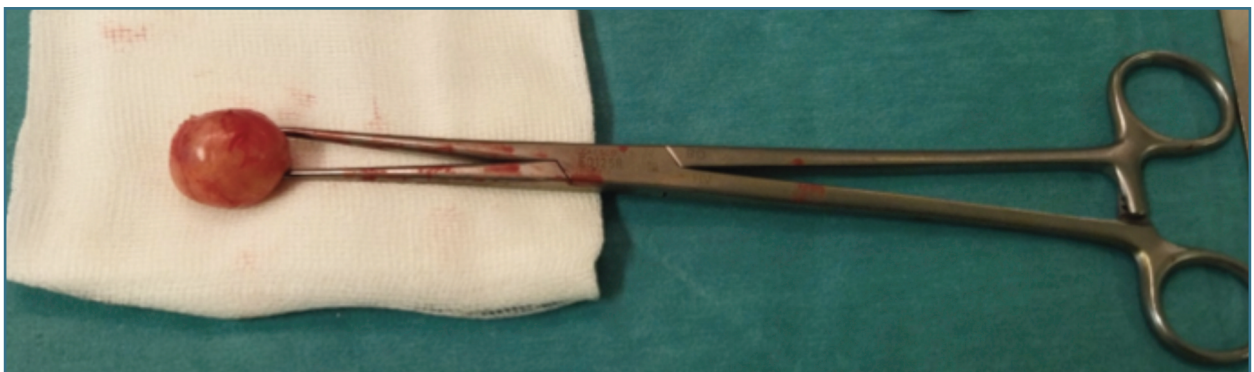As the vaginal mass had a close relation with the urethra, collaboration from Urology was requested and surgical excision decided. No invasion of the urethra was recognized.

A complete excision of the lesion through a longitudinal incision of the vaginal anterior wall was performed under general anaesthesia, with no complications (Figures 4 and 5).

After surgery, the patient had a favourable evolution and was discharged in the following day.

Macroscopic and histological examinations of the biopsy pieces showed morphological aspects of uterine smooth muscles tumours with uncertain malignancy potential (STUMP) (Figure 6).

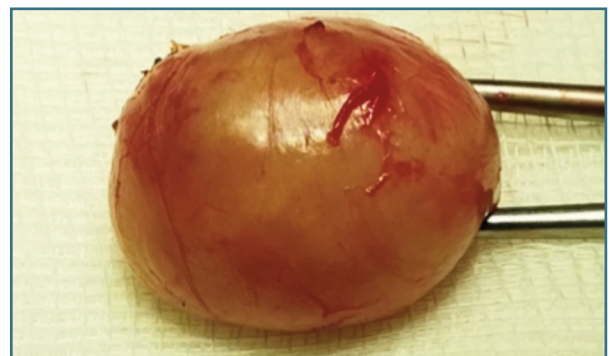The case was presented in our Multidisciplinary Tumour Board, and it was decided to maintain a close follow up in an oncological appointment with no additional surgery and no adjuvant therapy. A Thoraco-abdominal-pelvic computed tomography scan was made in the first year of follow-up and no imaging anomalies



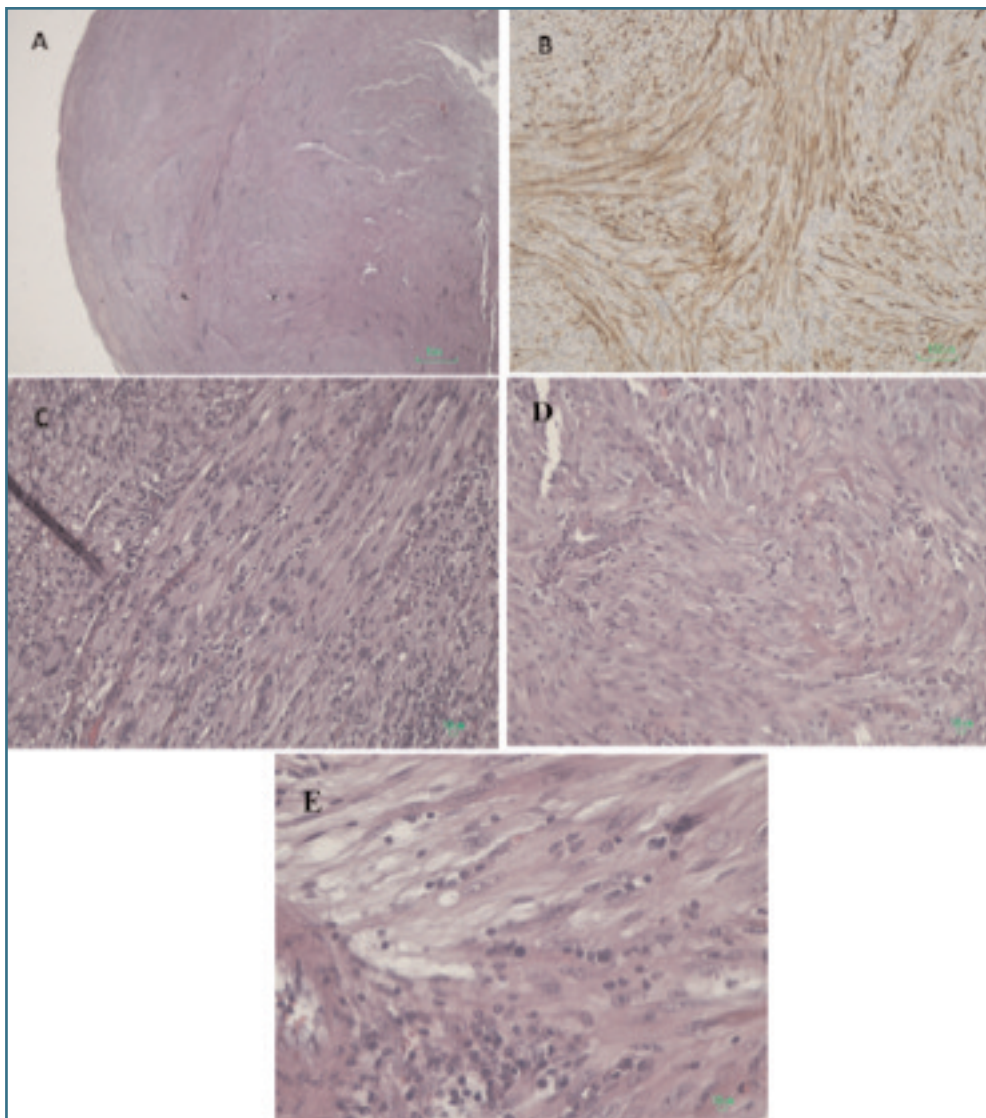
**FIGURE 4.** The excised lesion from the anterior wall of the vagina.

slightly vascularized and had an elastic consistency. Tumour markers and gynaecological ultrasound examination were normal.

Further pelvic magnetic resonance imaging revealed the presence of a nodular structure in the right anterolateral side of the lower third of the vagina, well-defined, with smooth and regular edges, posterior to the urethra, although with a cleavage plane, characteristics overlapping with a leiomyoma (Figure 3). Additionally, she presented multiple bilateral inguinal lymph node formations, with no criteria for adenomegaly.



**FIGURE 5.** Gross picture of the excised lesion following resection from the anterior wall of the vagina pressed by a pozzi forceps.



**FIGURE 6.** Microscopic features. **Image A:** fasciculated lesion with expansive limits. **Image B:** expression of smooth muscle actin (AE1/AE3, CD17, CD34, HMB45, Melan A and pS100 negatives). **Image C and D:** foci of moderate atypia with absence of necrosis. **Image E** demonstrates one of the rare mitoses, in the center.

were registered. Currently, the patient is asymptomatic, and no disease recurrence has been observed in a 2.5 years period of follow-up from the surgery.

## DISCUSSION

Vaginal smooth muscle tumours of uncertain malignant potential (STUMP) are extremely uncommon and remain a difficult diagnosis due to uncertainty between

malignancy and benign features. Surgical excision and histopathological analysis are the main form of final diagnosis<sup>1,5,8</sup>. Treatment decision is difficult in these cases and the radicality of the surgical approach must always be discussed with the patients<sup>12</sup>.

Considering the rarity of these tumours and even though STUMPs demonstrate a low-grade malignancy, existing literature on the topic is scarce and, therefore, their long-term clinical behaviour is not well defined. A long-term follow-up alongside with an

onco-gynaecologist is advised once a late relapse can occur<sup>6,8,12</sup>. With this case we expect to highlight the challenge that the management of vaginal STUMPs represents and the importance of creating practical guidelines for diagnosis, treatment, and follow-up of this disease.

## REFERENCES

- Dall'Asta, A.; Gizzo, S.; Musarò, A.; Quaranta, M.; Noventa, M.; Migliavacca, C.; Sozzi, G.; Monica, M.; Mautone, D.; Berretta, R. Uterine smooth muscle tumors of uncertain malignant potential (STUMP): Pathology, follow-up and recurrence. *Int. J. Clin. Exp. Pathol.* 2014, 7, 8136-8142.
- Bell, S.W.; Kempson, R.L.; Hendrickson, M.R. Problematic uterine smooth muscle neoplasms. A clinicopathologic study of 213 cases. *Am. J. Surg. Pathol.* 1994, 18, 535-558.
- Tinelli, A.; D'Oria, O.; Civino, E.; Morciano, A.; Hashmi, A.A.; Baldini, G.M.; tefanovic, R.; Malvasi, A.; Pecorella, G. Smooth Muscle Tumor of Uncertain Malignant Potential (STUMP): A Comprehensive Multidisciplinary Update. *Medicina* 2023, 59, 1371.
- Guntupalli SR, Ramirez PT, Anderson ML, et al. Uterine smooth muscle tumor of uncertain malignant potential: a retrospective analysis. *Gynecol Oncol* 2009;3:324-326.
- Ng JS, Han A, Chew SH, Low J. A clinicopathologic study of uterine smooth muscle tumours of uncertain malignant potential (STUMP). *Ann Acad Med Singapore* 2010;8:625-628.
- Lapresa-Alcalde, M.V.; Ruiz-Navarro, M.J.; Sancho de Salas, M.; Cubo, A.M. A Review and Follow-Up of Uterine Smooth Muscle Tumours of Uncertain Malignant Potential (STUMP): A Case Series and Literature Review. *Diseases* 2023, 11, 99.
- Liu, H.-T.; Wong, C.-N.; Liu, F.-S. Uterine smooth muscle tumor of uncertain malignant potential: A review of current knowledge. *Taiwan. J. Obstet. Gynecol.* 2022, 61, 935-940.
- Swanson AA, Howitt BE, Schoolmeester JK. Criteria for risk stratification of vulvar and vaginal smooth muscle tumors: a follow-up study with application to leiomyoma variants, smooth muscle tumors of uncertain malignant potential, and leiomyosarcomas. *Hum Pathol.* 2020 Sep;103:83-94. doi: 10.1016/j.humpath.2020.06.008. Epub 2020 Jul 17. PMID: 32687944.
- Ip PP, Cheung AN, Clement PB. Uterine smooth muscle tumors of uncertain malignant potential (STUMP): a clinicopathologic analysis of 16 cases. *Am J Surg Pathol* 2009;33:992-1005.
- Ip PP, Tse KY, Tam KF. Uterine smooth muscle tumors other than the ordinary leiomyomas and leiomyosarcomas: a review of selected variants with emphasis on recent advances and unusual morphology that may cause concern for malignancy. *Adv Anat Pathol* 2010;17:91-112.
- Guntupalli SR, Ramirez PT, Anderson ML, Milam MR, Bodurka DC, Malpica A. Uterine smooth muscle tumor of uncertain malignant potential: a retrospective analysis. *Gynecol Oncol* 2009; 113:324-6.
- Dall'Asta A, Gizzo S, Musarò A, Quaranta M, Noventa M, Migliavacca C, Sozzi G, Monica M, Mautone D, Berretta R. Uterine smooth muscle tumors of uncertain malignant potential (STUMP): pathology, follow-up and recurrence. *Int J Clin Exp Pathol.* 2014 Oct 15;7(11):8136-42.

## AUTHOR CONTRIBUTIONS

Lisandra Mendonça: Conceptualization, Writing – original draft, Writing – review and editing. Sónia Gonçalves: Writing – review and editing. António Santos Paulo: Writing – review. Nuno Dias: Writing – review and editing, Resources. Rita Mesquita Pinto: Writing – review and editing, Resources

## CONFLICT OF INTEREST

Authors declare they have no conflicts of interest.

## INFORMED CONSENT

The patient gave informed consent for publication.

## CORRESPONDENCE TO:

Lisandra Melo Mendonça  
E-mail: lisandramendonca18@gmail.com  
<https://orcid.org/0000-0002-1979-6390>

**RECEIVED:** 01/10/2024

**ACCEPTED:** 28/09/2025